

Frequency of Patent Foramen Ovale and Migraine in Patients With Cryptogenic Stroke

Brian H. West, MD*; Nabil Nouredin, MD*; Yakov Mamzhi, BS; Christopher G. Low, BS; Alexandra C. Coluzzi, BS; Evan J. Shih, MD; Rubine Gevorgyan Fleming, MD; Jeffrey L. Saver, MD; David S. Liebeskind, MD; Andrew Charles, MD; Jonathan M. Tobis, MD

Background and Purpose—Individuals with migraine are at higher risk for stroke, but the mechanism has not been established. On the basis of the association between migraine and intracardiac right-to-left shunt, it has been proposed that stroke in migraineurs could be caused by a paradoxical embolus passing through a patent foramen ovale (PFO) or pulmonary arteriovenous malformation. The aim of this study was to determine the prevalence of PFO with right-to-left shunt in patients who presented with cryptogenic stroke and had a history of migraine.

Methods—Patients between 18 and 60 years old who presented with an ischemic stroke were characterized based on ASCOD phenotyping (atherosclerosis; small-vessel disease; cardiac pathology; other causes; dissection). A migraine diagnosis was identified by reviewing physician notes, and frequent aura was defined if present in at least 50% of attacks. A PFO with right-to-left shunt diagnosis was identified by the presence of a positive bubble contrast study with either transcranial Doppler, transthoracic, or transesophageal echocardiography.

Results—Of the 712 patients who presented with ischemic stroke, 127 (18%) were diagnosed as cryptogenic; 68 patients had adequate testing for PFO and a documented migraine history. The prevalence of PFO in patients with cryptogenic stroke without migraine was elevated (59%) compared with the general population (18%). Patients with both cryptogenic stroke and migraine had a higher prevalence of PFO (79%). In patients with cryptogenic stroke who had migraine with frequent aura, the prevalence of PFO was 93%. Only 5 patients (4%) had a history compatible with migrainous infarction.

Conclusions—In patients with cryptogenic stroke who have migraine, there is a high prevalence (79%) of PFO with right-to-left shunt. The timing of the stroke in migraineurs is usually not related to a migraine attack. These observations are consistent with the hypothesis that the mechanism of stroke in migraineurs is most likely because of a paradoxical embolus. Future cryptogenic stroke classification schemes should consider including PFO as a separate etiologic category. (*Stroke*. 2018;49:00-00. DOI: 10.1161/STROKEAHA.117.020160.)

Key Words: cryptogenic stroke ■ migraine ■ patent foramen ovale

Epidemiological studies reveal that people who have a history of migraine headache with aura have a risk of developing a stroke that is 2.3× higher than in people without migraine.¹ This risk increases substantially in patients who smoke and use birth control pills, with an odds ratio for stroke as high as 13.9 (95% confidence interval [CI], 5.5–35.1).^{2–4} On the basis of the association between migraine, particularly migraine with aura, and intracardiac right-to-left shunt (RLS), it has been proposed that stroke in migraineurs could be because of a paradoxical embolus passing through a patent foramen ovale (PFO) or pulmonary arteriovenous malformation.⁵

The initial theory to explain the higher risk of stroke in migraineurs asserted that migraine was a vascular headache resulting from heightened cerebral arterial vasoreactivity.^{6–8} If the cerebral arterial spasm was excessive, then persistent

ischemia would result in a focal stroke. Although migraine attacks may be associated with cerebral oligemia, the reduction in blood flow (≈25%) rarely reaches the threshold for ischemia,⁹ and migrainous infarction is very uncommon.¹⁰ Migraine is no longer considered to be primarily a vascular headache, but rather it is a disorder of nervous system excitability where vascular alteration may occur but is not the predominant mechanism responsible for migraine symptoms. The hypothesis for this study was that the majority of patients, who presented with cryptogenic stroke and had a history of migraine, would also have a PFO with RLS.

Methods

The authors declare that all supporting data are available within the article. Approval for this review study was granted from the

Received November 17, 2017; final revision received February 16, 2018; accepted February 26, 2018.

From the Division of Cardiology, Department of Medicine, David Geffen School of Medicine at UCLA, Los Angeles, CA (B.H.W., Y.M., A.C.C., E.J.S., R.G.F., J.M.T.); Department of Internal Medicine, UNLV School of Medicine, Las Vegas, NV (N.N.); California Northstate University College of Medicine, Elk Grove (C.G.L.); and UCLA Department of Neurology, Los Angeles, CA (J.L.S., D.S.L., A.C.).

Guest Editor for this article was Stephen M. Davis, MD, FRACP.

*Drs West and Nouredin are co-first authors.

Correspondence to Jonathan M. Tobis, MD, Division of Cardiology, Department of Medicine, David Geffen School of Medicine at UCLA, Factor Bldg CHS, Room B-976, 10833 Le Conte Ave, Los Angeles, CA 90095. E-mail jtobis@mednet.ucla.edu

© 2018 American Heart Association, Inc.

Stroke is available at <http://stroke.ahajournals.org>

DOI: 10.1161/STROKEAHA.117.020160

University of California, Los Angeles, Institutional Review Board. Informed consent was waived by the Institutional Review Board. Patients between 18 and 60 years old who were diagnosed with stroke and came to the UCLA Comprehensive Stroke Center from January 1, 2008, to November 1, 2017, were identified. Cases of ischemic stroke were reviewed and clinically categorized based on ASCOD phenotyping (atherosclerosis; small-vessel disease; cardiac pathology; other causes; dissection) by the neurology evaluation in the medical records. ASCOD phenotyping categorizes the most likely cause of the ischemic stroke as either A: atherosclerosis; S: small-vessel disease; C: cardiac pathology (other than PFO); O: other causes; or D: dissection.¹¹ Cryptogenic stroke was defined as those patients who had no other obvious cause for their stroke after an evaluation by neurology which included medical history, a brain magnetic resonance imaging, evaluation of the carotid arteries and aortic arch, cardiac evaluation by transthoracic echocardiography (TTE) or transesophageal echocardiography (TEE), and monitoring for arrhythmias such as atrial fibrillation. A migraine diagnosis was identified by reviewing the neurology notes in the electronic medical record. A migraine with frequent aura diagnosis was defined in individuals experiencing aura in at least 50% of migraine attacks. A PFO with RLS diagnosis was identified by the presence of a positive bubble contrast study with either TTE, TEE, or transcranial Doppler (TCD). TCD has been demonstrated to have higher sensitivity for detection of RLS when compared with contrast TEE and is superior to TTE.^{12,13} It is important to note that although the TCD examination reveals the presence of an RLS, it does not distinguish between a PFO and pulmonary arteriovenous malformation. However, in our experience of 1500 TCD studies, the rate of pulmonary arteriovenous malformation is only 1% in patients referred without hereditary hemorrhagic telangiectasia (Tobis J, unpublished data, 2017); similar results have been demonstrated in the literature, and thus, a positive RLS examination was used to define the prevalence of PFO.^{14,15} Using passage of a guidewire across the atrial septum during cardiac catheterization with intracardiac echocardiography guidance as the standard for diagnosing a PFO, TCD \geq grade 3 has 98% sensitivity for making the diagnosis of PFO.¹⁶ The degree of RLS was evaluated by TCD at rest and with the Valsalva maneuver. The Spencer logarithmic scale was used to grade the results; a grade of ≥ 2 (>10 embolic tracks/60 s) was considered positive for a significant shunt, which has a 97% sensitivity and 100% specificity for the diagnosis of PFO.¹²

Comparisons in PFO prevalence were made between patients with cryptogenic stroke without migraine, cryptogenic stroke with migraine, and cryptogenic stroke with migraine with aura using Fisher exact test. PFO prevalence in patients with cryptogenic stroke was compared with estimates of PFO in the general population. After identifying patients with both migraine and stroke, the frequency of a diagnosis of migrainous infarction was investigated. A migrainous infarction was defined as a typical migraine for that patient that begins with aura or their usual cephalgic pain but progresses into a clinical stroke that is documented with a lesion on brain magnetic resonance imaging.^{10,17}

Results

A total of 1255 patients between 18 and 60 years of age were identified in the stroke database of the UCLA Comprehensive Stroke Center from January 1, 2008, to November 1, 2017. The upper age limit was set at 60 years as part of the definition of cryptogenic stroke. The stroke types were divided into ischemic 712 of 1255 (57%), intracerebral hemorrhage 293 of 1255 (23%), subarachnoid hemorrhage 183 of 1255 (15%), and transient ischemic attack 67 of 1255 (5%). On the basis of ASCOD phenotyping,¹¹ the cause of the 712 ischemic strokes was further divided into the following categories: atherosclerosis 151 of 712 (21%), small artery disease 51 of 712 (7%), cardiac (other than PFO) 165 of 712 (23%), other 105 of 712 (15%), and dissection 113 of 712 (16%). The remainder of the

cases were considered cryptogenic in 127 of the 712 ischemic strokes (18%; Figure 1).

Of the 127 patients with cryptogenic stroke, 68 (54%) had adequate testing to determine the presence of a PFO with RLS (by contrast TTE, TEE, or TCD) and a complete migraine history. Of the 68 cryptogenic stroke patients who had adequate testing for the presence of an RLS, 47 of 68 (69%) had a PFO. PFO with RLS was identified in 8 patients (17%) via TTE, 16 patients (34%) via TEE, 6 patients (13%) via TCD, and 17 patients (36%) via both TEE and TCD. All of the patients diagnosed via TCD had shunts that were Spencer grade ≥ 2 .

Of the 68 cryptogenic stroke patients who had adequate testing for the presence of an RLS, 34 (50%) had migraine; and 15 of these 34 (44%) migraine patients had frequent aura (Figure 2). Of the 34 patients who had cryptogenic stroke and migraine, 27 (79%) had a PFO, and of the 34 patients with cryptogenic stroke who did not have migraine, 20 (59%) had a PFO. Moreover, of the 15 patients with both cryptogenic stroke and migraine with frequent aura, 14 (93%) had a PFO (Figure 3). The difference in prevalence of PFO between patients with cryptogenic stroke without migraine, with migraine, and with migraine with aura was statistically significant ($P=0.042$).

When compared with a control general population of 200 people where the prevalence of PFO was 18% as determined by a TCD grade ≥ 3 , patients with cryptogenic stroke with or without migraine had significantly greater prevalence of PFO (χ^2 , $P<0.00001$ and χ^2 , $P<0.00001$, respectively).¹⁸

Five of the 128 (4%) patients who had cryptogenic stroke presented with a history that was compatible with a migrainous infarction. All 5 of these patients had a prior history of migraine. Two of the 5 (40%) patients with possible migrainous infarction had a PFO.

Discussion

Our results from a database of all subjects who presented with a stroke to 1 academic medical center demonstrate a high prevalence of PFO (69%) in patients with cryptogenic stroke. Prior studies showed estimates of PFO in the cryptogenic stroke population between 38% and 48%, with slight differences based on patient age.¹⁹ Only TTE was used to detect abnormalities in the atrial septum in these groups of patients, and thus, a significant number of PFOs may have been missed. A subsequent meta-analysis found a broader range in the incidence of PFO in the cryptogenic stroke population, between 31% and 77%; these differences were largely attributed to differences in detection technique.²⁰

In addition, our results show a high prevalence of migraine (50%) in patients with cryptogenic stroke. These results corroborate the findings of a study which demonstrated that migraine increased the odds of cryptogenic events, both TIA and stroke, with an odds ratio of 1.73 (95% CI, 1.38–2.16) relative to those without migraine.²¹ This effect may reflect an underlying association of both migraine and cryptogenic stroke with PFO.²²

The literature is mixed on the relationship between migraine and PFO. One large study did not find a significant association between PFO and increased prevalence of migraine (odds ratio, 1.01; 95% CI, 0.63–1.61) or migraine with aura (odds ratio, 1.01; 95% CI, 0.71–1.69).²³ It should be noted that this

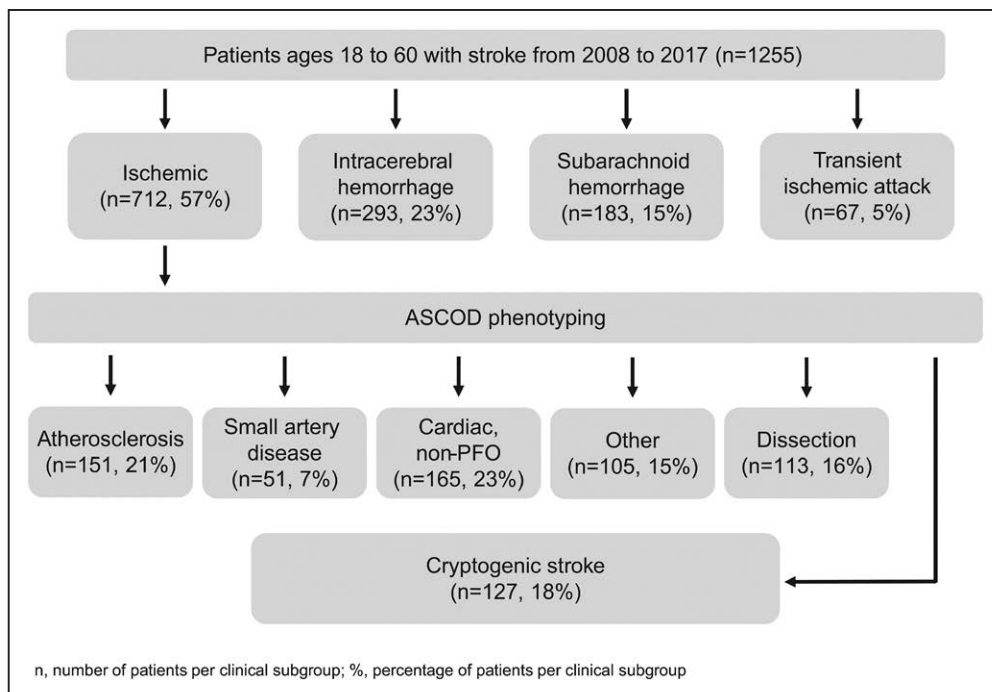


Figure 1. Flowchart for patient selection. PFO indicates patent foramen ovale.

study excluded patients with a history of stroke. A meta-analysis, which did include patients with a history of stroke, found a significant bidirectional relationship between PFO and migraine.²⁴ The prevalence of migraine in patients with PFO relative to those without PFO was characterized by an odds ratio of 5.13 (95% CI, 4.67–5.59), with significant results for the subgroup of patients who had migraine with aura; the prevalence of PFO in patients with migraine relative to those without migraine, independent of aura, was characterized

by an odds ratio of 2.54 (95% CI, 2.01–3.08). These differences in the literature may be related to the inclusion of stroke patients in the study population, and what has been described as a triad of cryptogenic stroke, PFO, and migraine with aura.

Wilmshurst et al⁵ was the first to report that there was a high association of PFO in migraineurs who developed a stroke. In his study of 60 patients who presented with a stroke and had a history of migraine with aura, 84% had evidence of a PFO with an RLS. In our study, patients with both cryptogenic stroke

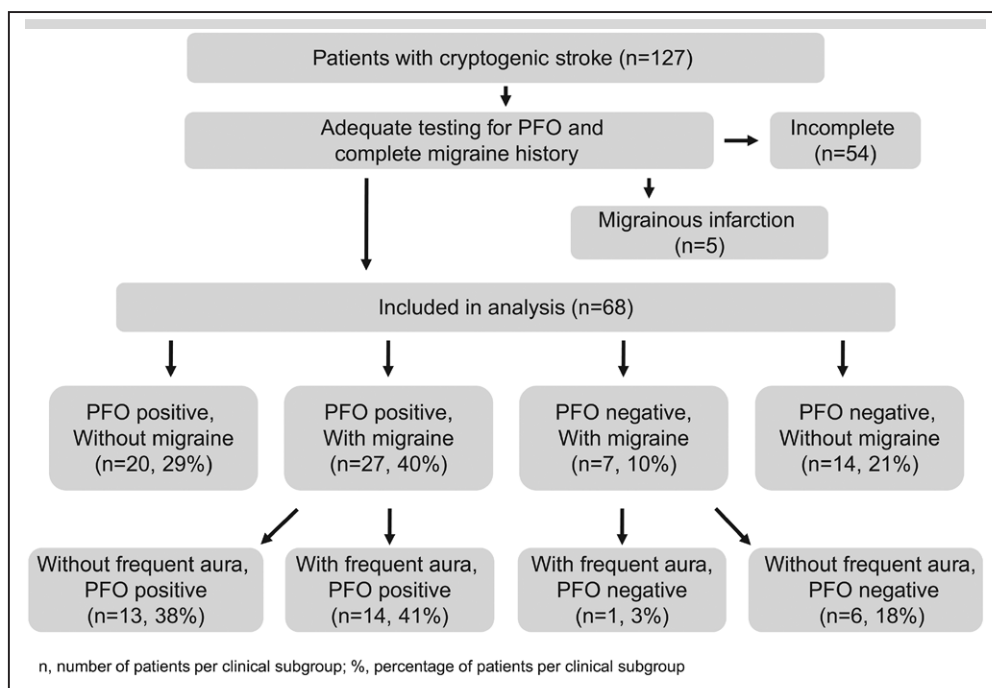


Figure 2. Flowchart for patient selection. PFO indicates patent foramen ovale.

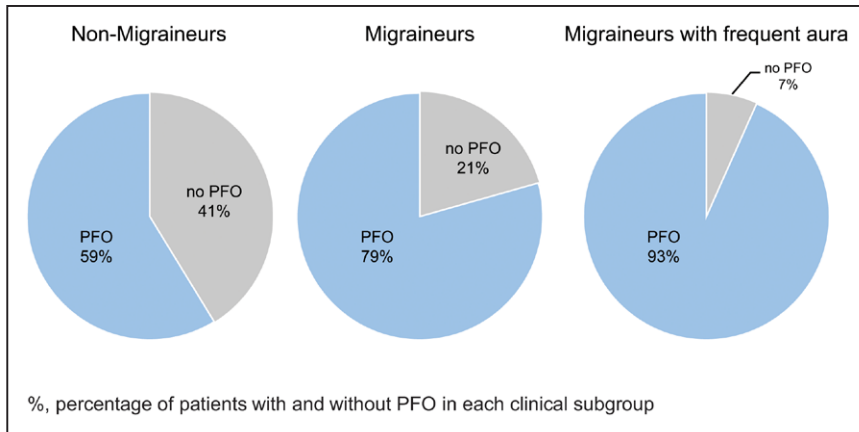


Figure 3. Prevalence of patent foramen ovale (PFO) in patients with cryptogenic stroke.

and migraine had a high prevalence of PFO (79%), which is similar to the frequency that was reported by Wilmshurst et al.⁵ In the subset of patients with cryptogenic stroke who had migraine with frequent aura, the prevalence of PFO was also very high (93%). One explanation for this observation is that migraine with frequent aura may be a marker for the presence of PFO.²⁵ The prevalence of PFO in patients with cryptogenic stroke without migraine was also elevated (59%), and the prevalence of PFO in each group was significantly higher than in a general population of 200 subjects at UCLA (18%).¹⁸

Many studies have highlighted the association between migraine with aura and PFO.^{24,26,27} The PREMIUM trial (Prospective, Randomized Investigation to Evaluate Incidence of Headache Reduction in Subjects With Migraine and PFO Using the AMPLATZER PFO Occluder to Medical Management) prospectively randomized 230 patients with PFO and medically refractory migraine (with or without aura) to PFO closure versus a sham procedure. Although the primary end point of 50% reduction of migraine attacks was not met, there was a significant reduction in mean headache days per month (-3.4 ± 4.4 d/mo in the PFO closure arm versus -2.0 ± 5.0 d/mo in the sham procedure arm, $P=0.03$) and a strong treatment response for the subgroup who had migraine with frequent aura (49% responded in the PFO closure group versus 23% in the sham procedure group, $P=0.015$, with response defined as at least a 50% reduction in migraine attacks per month).²⁸ Moreover, in all migraineurs, complete remission occurred in 8.5% of the closure group, compared with only 1% of the sham group ($P=0.01$), suggesting that PFO may be causally related in some migraineurs.

The mechanism of migraine reduction via PFO closure is not entirely clear, though the association with cryptogenic stroke may provide insight into this relationship. Several theories have been proposed on the relationship between migraine and PFO because of RLS of blood. Chemical triggers of migraine that are normally metabolized in the lung could bypass the pulmonary circulation through a PFO and thereby enter the cerebral circulation in higher concentrations. Alternatively, deoxygenated venous blood entering the arterial system through a PFO could be sufficient to trigger a migraine in susceptible individuals.^{29,30}

There is also evidence to suggest that release of platelet serotonin may play a role in the development of migraine in patients with RLS. It has been proposed that platelets, as a result of shear stress, may become activated and release

serotonin, ultimately leading to migraine; this process may be initiated by cardiovascular abnormalities, such as PFO.^{31,32} There are also data that mitral valve prolapse may similarly be implicated in migraine pathophysiology. It has been proposed that platelet damage from the mitral valve regurgitant jet could induce platelet damage and lead to release of serotonin.³² Interestingly, data have shown a significantly higher prevalence of mitral valve prolapse in patients with migraine versus control patients, with an odds ratio of 2.7 (95% CI, 1.17–6.29).³³

Microemboli have also been proposed as a migraine trigger. Small venous blood clots or platelet aggregates, which normally would be trapped by the lungs (and thus remain clinically silent), may act as a potential trigger for migraine when introduced into the arterial circulation through an RLS.^{34,35} Animal experiments support this hypothesis; microemboli have been shown to trigger cortical spreading depression, the slow cerebral depolarization underlying migraine with aura.³⁶ Moreover, this theory of paradoxical microembolism provides a direct connection between PFO, migraine, and stroke, as larger emboli could attain a sufficient threshold of cerebral ischemia to produce an infarct.

Although more studies are needed to further elucidate these various theories, the relationship between stroke and migraine is unlikely to be explained primarily by vasoconstriction leading to infarction. Previous radiopharmaceutical scans have shown that cerebral blood flow only decreases by 25% from baseline during migraine, which would not be sufficient to cause tissue necrosis.⁹ Instead, the significant association between cryptogenic stroke, migraine, and PFO suggests that stroke in migraineurs may be mediated by a PFO pathway in the majority of cases. Our data support this latter hypothesis as the majority of patients in our study had overlap of cryptogenic stroke, migraine, and PFO, but only 3 patients had a presentation consistent with migrainous infarction without the presence of an RLS.

Our results were limited by the adequacy of testing for PFO, and the selection bias inherent in a cohort of patients who underwent more thorough testing for RLS. Patients are often recommended for a TTE with bubble study to rule out PFO. Even at the UCLA Stroke Center of Excellence, in which stroke cause is extensively investigated in all patients, TTE with bubble study was often the primary imaging modality ordered, especially in the earlier years of this database. This can produce false-negative results in over 50% of cases, as evidenced by a meta-analysis which included over 3000 patients.³⁷ In our study

population, only 54% of patients with cryptogenic stroke had both sufficient PFO testing and a complete migraine history performed. It is possible that many patients had PFOs that went undiagnosed. These data suggest that when a cause for stroke is not identified, before classifying a patient as cryptogenic, a TEE or TCD with agitated saline contrast should be obtained. This becomes particularly important in patients with a history of migraine, especially if they also experience aura. It should be emphasized that TCD saline studies are not only more predictive than TEE for detection of RLS but also more predictive of recurrent events.³⁸ Moreover, TEE misses 15% of RLS detected with TCD saline studies, and large shunts on TCD predict recurrent stroke better than the presence of a shunt on TEE.³⁸

The value of obtaining a thorough headache history in patients who present with cryptogenic stroke should be emphasized; a simple headache questionnaire, such as the Migraine Prevention Questionnaire 5, can be used for this purpose.³⁹ Physicians must also be mindful of important clinical clues that are suggestive of paradoxical embolism in patients with cryptogenic stroke. Data have shown that individuals with paradoxical embolism are more likely to present with dyspnea or a Valsalva maneuver at the onset of stroke, waking up with stroke, a history of deep vein thrombosis, pulmonary embolism or the presence of varicose veins, or a history of sleep apnea.⁴⁰

The ultimate test for whether a PFO is present is not an agitated saline bubble study but is a right heart catheterization with a guidewire to probe the atrial septum under intracardiac echo imaging or injection of contrast against the foramen ovale. In those patients who had a stroke and a history of migraine but do not have a positive study demonstrating an RLS, misdiagnosis is one possible explanation; migrainous stroke is another explanation, but if a PFO is not present, the cause in these cases is truly cryptogenic.

Our results were also limited by a migraine diagnosis that was made without the consistent use of formal International Classification of Headache Disorders criteria.⁴¹ Previous studies have found, however, that patient- or physician-identified migraine is corroborated by International Classification of Headache Disorders criteria in the overwhelming majority of cases, such that the accuracy of diagnosis in our study is likely to be high.⁴² Nonetheless, migraine may be underreported in our study based on lack of patient or physician reporting.

Another limitation of this study is its retrospective, observational nature without a comparison group, and the biases inherent in this design. Moreover, the associations we found do not prove causality; instead they are hypothesis generating and highlight relationships that exist between cryptogenic stroke, migraine, and PFO. The original study by Wilmshurst et al⁵ that identified an increased incidence of PFO in migraineurs who developed a stroke focused on patients who were referred specifically for workup for paradoxical embolism. Our study instead started with a large, heterogeneous database of all stroke patients and then retrospectively identified those with migraine who were tested for a PFO. This strengthens the generalizability of the results in that this cohort represents the entirety of the stroke population at 1 referral institution and emphasizes the high incidence of undiagnosed PFO and migraine in this group. Future studies should continue to target this population and further elucidate relationships in the triad of stroke, migraine, and PFO.

The current stroke classification scheme does not include a separate category for PFO. The cardiac subcategory that does exist excludes PFO and is reserved for clot originating on the left side of the heart. On the basis of our results of the high degree to which PFO is implicated in patients currently classified as cryptogenic, future stroke classification schemes should consider including PFO as a separate etiologic category. If there is a stroke without an obvious ASCOD cause but a PFO is present, it is no longer sufficient to define this as cryptogenic, but could be categorized as a PFO-associated stroke. Further support for having a PFO-associated stroke as a separate etiologic category comes from the RESPECT (Randomized Evaluation of Recurrent Stroke Comparing PFO Closure to Established Current Standard of Care Treatment) and REDUCE (GORE® HELEX® Septal Occluder / GORE® CARDIOFORM Septal Occluder for Patent Foramen Ovale [PFO] Closure in Stroke Patients - The Gore REDUCE Clinical Study) randomized trials, which demonstrated a significant reduction in recurrent stroke for subjects who had their PFO closed percutaneously: hazard ratio, 0.55; 95% CI, 0.31–0.999; $P=0.046$ and relative risk, 0.51; 95% CI, 0.29–0.91; $P=0.04$, respectively, which provides evidence that PFO is causally related to cryptogenic stroke.^{43,44}

Acknowledgments

We thank the UCLA Specialty Training and Advanced Research (STAR) program for support of this project. We also Dr David Elashoff for his help with the statistical aspects of this project.

Sources of Funding

This project was partially funded by National Institutes of Health grant 5T32HL007895-19; Principal Investigator: Dr James N. Weiss.

Disclosures

Dr Saver received contracted hourly payments from St. Jude Medical for service on trial Steering Committees, advising on rigorous study design and implementation. The other authors report no conflicts.

References

1. Spector JT, Kahn SR, Jones MR, Jayakumar M, Dalal D, Nazarian S. Migraine headache and ischemic stroke risk: an updated meta-analysis. *Am J Med.* 2010;123:612–624. doi: 10.1016/j.amjmed.2009.12.021.
2. MacClellan LR, Giles W, Cole J, Wozniak M, Stern B, Mitchell BD, et al. Probable migraine with visual aura and risk of ischemic stroke: the stroke prevention in young women study. *Stroke.* 2007;38:2438–2445. doi: 10.1161/STROKEAHA.107.488395.
3. Etmnan M, Takkouche B, Isorna FC, Samii A. Risk of ischaemic stroke in people with migraine: systematic review and meta-analysis of observational studies. *BMJ.* 2005;330:63. doi: 10.1136/bmj.38302.504063.8F.
4. Tzourio C, Tehindrazanarivo A, Iglésias S, Alperovitch A, Chedru F, d'Anglejan-Chatillon J, et al. Case-control study of migraine and risk of ischaemic stroke in young women. *BMJ.* 1995;310:830–833.
5. Wilmshurst P, Nightingale S, Pearson M, Morrison L, Walsh K. Relation of atrial shunts to migraine in patients with ischemic stroke and peripheral emboli. *Am J Cardiol.* 2006;98:831–833. doi: 10.1016/j.amjcard.2006.03.070.
6. Tunis MM, Wolff HG. Studies on headache; long-term observations of the reactivity of the cranial arteries in subjects with vascular headache of the migraine type. *AMA Arch Neurol Psychiatry.* 1953;70:551–557.
7. Dalessio DJ. Cerebral vasospasm in migraine. *J Lancet.* 1967;87:283–286.
8. Thie A, Spitzer K, Lachenmayer L, Kunze K. Prolonged vasospasm in migraine detected by noninvasive transcranial Doppler ultrasound. *Headache.* 1988;28:183–186.
9. Lauritzen M, Skyhøj Olsen T, Lassen NA, Paulson OB. Changes in regional cerebral blood flow during the course of classic migraine attacks. *Ann Neurol.* 1983;13:633–641. doi: 10.1002/ana.410130609.

10. Laurell K, Lundström E. Migrainous infarction: aspects on risk factors and therapy. *Curr Pain Headache Rep.* 2012;16:255–260. doi: 10.1007/s11916-012-0262-2.
11. Amarenco P, Bogousslavsky J, Caplan LR, Donnan GA, Wolf ME, Hennerici MG. The ASCOD phenotyping of ischemic stroke (Updated ASCO Phenotyping). *Cerebrovasc Dis.* 2013;36:1–5. doi: 10.1159/000352050.
12. Mojadidi MK, Roberts SC, Winoker JS, Romero J, Goodman-Meza D, Gevorgyan R, et al. Accuracy of transcranial Doppler for the diagnosis of intracardiac right-to-left shunt: a bivariate meta-analysis of prospective studies. *JACC Cardiovasc Imaging.* 2014;7:236–250. doi: 10.1016/j.jcmg.2013.12.011.
13. Mojadidi MK, Bogush N, Caceres JD, Msaouel P, Tobis JM. Diagnostic accuracy of transeophageal echocardiogram for the detection of patent foramen ovale: a meta-analysis. *Echocardiography.* 2014;31:752–758. doi: 10.1111/echo.12462.
14. Goutman SA, Katzan IL, Gupta R. Transcranial Doppler with bubble study as a method to detect extracardiac right-to-left shunts in patients with ischemic stroke. *J Neuroimaging.* 2013;23:523–525. doi: 10.1111/j.1552-6569.2012.00738.x.
15. Puledda F, Toscano M, Pieroni A, Veneroso G, Di Piero V, Vicenzini E. Right-to-left shunt detection sensitivity with air-saline and air-succinyl gelatin transcranial Doppler. *Int J Stroke.* 2016;11:229–238. doi: 10.1177/1747493015609938.
16. Spencer MP, Moehring MA, Jesurum J, Gray WA, Olsen JV, Reisman M. Power m-mode transcranial Doppler for diagnosis of patent foramen ovale and assessing transcatheter closure. *J Neuroimaging.* 2004;14:342–349. doi: 10.1177/1051228404268743.
17. Headache Classification Subcommittee of the International Headache Society. The International Classification of Headache Disorders: 2nd edition. *Cephalalgia.* 2004;24:9–160.
18. Mojadidi MK, Khessali H, Gevorgyan R, Levinson RD, Tobis JM. Visual migraine aura with or without headache: association with right to left shunt and assessment following transcatheter closure. *Clin Ophthalmol.* 2012;6:1099–1105. doi: 10.2147/OPHTH.S30999.
19. Di Tullio M, Sacco RL, Gopal A, Mohr JP, Homma S. Patent foramen ovale as a risk factor for cryptogenic stroke. *Ann Intern Med.* 1992;117:461–465.
20. Overell JR, Bone I, Lees KR. Interatrial septal abnormalities and stroke: a meta-analysis of case-control studies. *Neurology.* 2000;55:1172–1179.
21. Li L, Schulz UG, Kuker W, Rothwell PM; Oxford Vascular Study. Age-specific association of migraine with cryptogenic TIA and stroke: population-based study. *Neurology.* 2015;85:1444–1451. doi: 10.1212/WNL.0000000000002059.
22. Tobis MJ, Azarbal B. Does patent foramen ovale promote cryptogenic stroke and migraine headache? *Tex Heart Inst J.* 2005;32:362–365.
23. Rundeck T, Elkind MS, Di Tullio MR, Carrera E, Jin Z, Sacco RL, et al. Patent foramen ovale and migraine: a cross-sectional study from the Northern Manhattan Study (NOMAS). *Circulation.* 2008;118:1419–1424. doi: 10.1161/CIRCULATIONAHA.108.771303.
24. Schwedt TJ, Demaerschalk BM, Dodick DW. Patent foramen ovale and migraine: a quantitative systematic review. *Cephalalgia.* 2008;28:531–540. doi: 10.1111/j.1468-2982.2008.01554.x.
25. Del Sette M, Angeli S, Leandri M, Ferriero G, Bruzzone GL, Finocchi C, et al. Migraine with aura and right-to-left shunt on transcranial Doppler: a case-control study. *Cerebrovasc Dis.* 1998;8:327–330. doi: 10.1159/000015875.
26. Takagi H, Umemoto T; ALICE (All-Literature Investigation of Cardiovascular Evidence) Group. A meta-analysis of case-control studies of the association of migraine and patent foramen ovale. *J Cardiol.* 2016;67:493–503. doi: 10.1016/j.jicc.2015.09.016.
27. Domitrz I, Mieszkowski J, Kamińska A. Relationship between migraine and patent foramen ovale: a study of 121 patients with migraine. *Headache.* 2007;47:1311–1318. doi: 10.1111/j.1526-4610.2006.00724.x.
28. Tobis JM, Charles A, Silberstein SD, Sorensen S, Maini B, Horwitz PA, et al. Percutaneous closure of patent foramen ovale in patients with migraine: The PREMIUM Trial. *J Am Coll Cardiol.* 2017;70:2766–2774. doi: 10.1016/j.jacc.2017.09.1105.
29. Schoonman GG, Sándor PS, Agosti RM, Siccoli M, Bärtsch P, Ferrari MD, et al. Normobaric hypoxia and nitroglycerin as trigger factors for migraine. *Cephalalgia.* 2006;26:816–819. doi: 10.1111/j.1468-2982.2006.01112.x.
30. Arnglim N, Schytz HW, Britze J, Amin FM, Vestergaard MB, Hougaard A, et al. Migraine induced by hypoxia: an MRI spectroscopy and angiography study. *Brain.* 2016;139(pt 3):723–737. doi: 10.1093/brain/awv359.
31. Borgdorff P, Tangelder GJ. Migraine: possible role of shear-induced platelet aggregation with serotonin release. *Headache.* 2012;52:1298–1318. doi: 10.1111/j.1526-4610.2012.02162.x.
32. Spence JD. Migraine, shear stress, and platelet serotonin. *Headache.* 2013;53:552. doi: 10.1111/head.12010.
33. Spence JD, Wong DG, Melendez LJ, Nichol PM, Brown JD. Increased prevalence of mitral valve prolapse in patients with migraine. *Can Med Assoc J.* 1984;131:1457–1460.
34. Meier B, Lock JE. Contemporary management of patent foramen ovale. *Circulation.* 2003;107:5–9.
35. Fuller CJ, Jesurum JT. Migraine and patent foramen ovale: state of the science. *Crit Care Nurs Clin North Am.* 2009;21:471–491. doi: 10.1016/j.ccell.2009.07.011.
36. Nozari A, Dilekoz E, Sukhotinsky I, Stein T, Eikermann-Haerter K, Liu C, et al. Microemboli may link spreading depression, migraine aura, and patent foramen ovale. *Ann Neurol.* 2010;67:221–229. doi: 10.1002/ana.21871.
37. Katsanos AH, Psaltopoulou T, Sergeantanis TN, Frogoudaki A, Vrettou AR, Ikonomidis I, et al. Transcranial Doppler versus transthoracic echocardiography for the detection of patent foramen ovale in patients with cryptogenic cerebral ischemia: a systematic review and diagnostic test accuracy meta-analysis. *Ann Neurol.* 2016;79:625–635. doi: 10.1002/ana.24609.
38. Tobe J, Bogiatzi C, Munoz C, Tamayo A, Spence JD. Transcranial doppler is complementary to echocardiography for detection and risk stratification of patent foramen ovale. *Can J Cardiol.* 2016;32:986.e9–986.e16. doi: 10.1016/j.cjca.2015.12.009.
39. Buse DC, Rupnow MF, Lipton RB. Assessing and managing all aspects of migraine: migraine attacks, migraine-related functional impairment, common comorbidities, and quality of life. *Mayo Clin Proc.* 2009;84:422–435. doi: 10.1016/S0025-6196(11)60561-2.
40. Ozdemir AO, Tamayo A, Munoz C, Dias B, Spence JD. Cryptogenic stroke and patent foramen ovale: clinical clues to paradoxical embolism. *J Neurol Sci.* 2008;275:121–127. doi: 10.1016/j.jns.2008.08.018.
41. Headache Classification Committee of the International Headache Society (IHS). The International Classification of Headache Disorders, 3rd edition (beta version). *Cephalalgia.* 2013;33:629–808. doi: 10.1177/0333102413485658.
42. Tepper SJ, Dahlöf CG, Dowson A, Newman L, Mansbach H, Jones M, et al. Prevalence and diagnosis of migraine in patients consulting their physician with a complaint of headache: data from the Landmark Study. *Headache.* 2004;44:856–864. doi: 10.1111/j.1526-4610.2004.04167.x.
43. Saver JL, Carroll JD, Thaler DE, Smalling RW, MacDonald LA, Marks DS, et al; RESPECT Investigators. Long-term outcomes of patent foramen ovale closure or medical therapy after stroke. *N Engl J Med.* 2017;377:1022–1032. doi: 10.1056/NEJMoa1610057.
44. Søndergaard L, Kasner SE, Rhodes JF, Andersen G, Iversen HK, Nielsen-Kudsk JE, et al; Gore REDUCE Clinical Study Investigators. Patent foramen ovale closure or antiplatelet therapy for cryptogenic stroke. *N Engl J Med.* 2017;377:1033–1042. doi: 10.1056/NEJMoa1707404.

Stroke

JOURNAL OF THE AMERICAN HEART ASSOCIATION



Frequency of Patent Foramen Ovale and Migraine in Patients With Cryptogenic Stroke

Brian H. West, Nabil Nouredin, Yakov Mamzhi, Christopher G. Low, Alexandra C. Coluzzi, Evan J. Shih, Rubine Gevorgyan Fleming, Jeffrey L. Saver, David S. Liebeskind, Andrew Charles and Jonathan M. Tobis

Stroke. published online April 10, 2018;
Stroke is published by the American Heart Association, 7272 Greenville Avenue, Dallas, TX 75231
Copyright © 2018 American Heart Association, Inc. All rights reserved.
Print ISSN: 0039-2499. Online ISSN: 1524-4628

The online version of this article, along with updated information and services, is located on the World Wide Web at:

<http://stroke.ahajournals.org/content/early/2018/04/09/STROKEAHA.117.020160>

Permissions: Requests for permissions to reproduce figures, tables, or portions of articles originally published in *Stroke* can be obtained via RightsLink, a service of the Copyright Clearance Center, not the Editorial Office. Once the online version of the published article for which permission is being requested is located, click Request Permissions in the middle column of the Web page under Services. Further information about this process is available in the [Permissions and Rights Question and Answer](#) document.

Reprints: Information about reprints can be found online at:
<http://www.lww.com/reprints>

Subscriptions: Information about subscribing to *Stroke* is online at:
<http://stroke.ahajournals.org/subscriptions/>